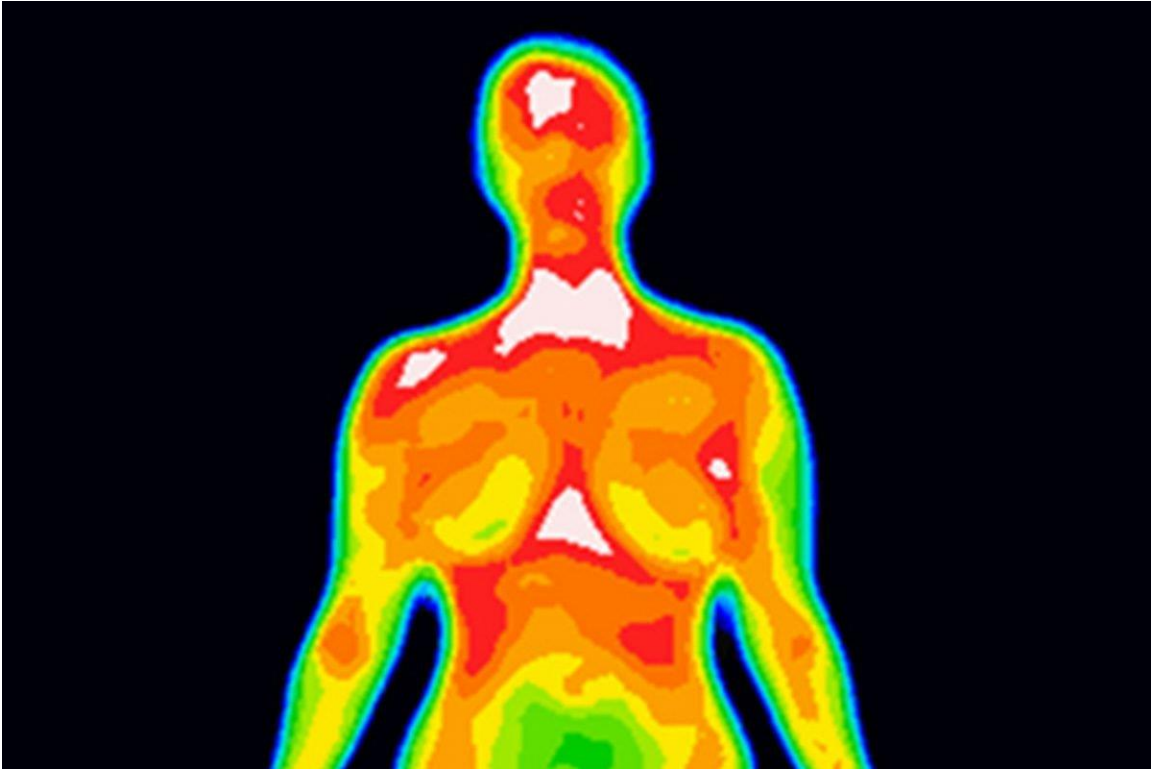


Thermography: The Heat is On



Introduction:

It is ironic that with the incredible progress that has been made in detecting potentially curable cancer with modern screening devices (3-D mammography, U.S. and MRI), an unproven technology is gaining momentum as an alternative to mammography

Thermography is now being aggressively promoted as a **substitute for mammograms**. It is easy to understand the argument in favor of thermography. It is painless and does not require exposure to radiation. A third argument, that is not usually discussed, is that it can be a “money maker” for physicians. Some physicians have gone so far as to advertise that thermography can detect breast

- 1.

cancers eight years before they can be detected on the mammogram. There is, of course, zero evidence to support this claim.

FDA recommendations:

The FDA does not approve of thermography as an independent breast cancer-screening device. It is only approved as an adjunct to standard mammography screening. As a result, insurance companies are not required to cover the cost of a thermogram, and their cash price can exceed \$600 dollars. The FDA explanation for **lack of coverage is the lack of evidence of value.**

The potential for the thermogram to detect a breast cancer in asymptomatic women is base on the concept of heat. For a cancer to grow, it requires a blood supply. A focal increase in blood flow should in theory result in a focal increase in heat as compared to surrounding breast tissue. The thermogram is designed to detect that increased heat. The concept is credible, but there is simply no evidence that the thermogram can differentiate between the heat caused by normal variation in blood flow and focal increases in heat associated with a **small** growing cancer.

Case in Point:

I recently cared for a patient who found a lump in her right breast. It seemed to be growing in size so she obtained a thermogram, which proved to be normal. The mass continued to grow and several months later she repeated the study. Again, it was normal.

She made an appointment to see me. On exam, I felt a suspicious mass in the area of her concern. A mammogram confirmed my suspicions and the core needle was positive for an invasive ductal cancer.

Conclusion:

This case clearly demonstrates the limitation of a thermogram even in the case of a
2.

cancer that was almost an inch in diameter. However, there is a second and even more important drawback. **A negative thermogram gives a woman a false feeling of security that “all is well”** when in reality thermograms can miss small and potentially curable breast cancers that are easily detected on standard breast imaging. In short, diagnostic delays associated with a **“false negative” thermogram** can lead to diagnostic delays that can potentially increase a woman’s risk of dying from breast cancer.

My conclusion is that a thermogram causes more harm than good and should be avoided at all costs. However, the FDA has approved this technology as an adjunct to mammography. Their recommendation is much like taking chicken soup for the flu.... “It can’t hurt”. This may be true for chicken soup and the flu, but definitely not true for thermograms and breast cancer.

I would like to invite anyone who is an advocate for thermography to respond. Please contact me at _____ if you have questions or suggestions.

3.

The End